



Jornada de cirugía de campo en la Cornisa
Santander 16 noviembre 2019

Hernias umbilicales

Luis Rubio-Martínez

LV DVSc PhD

Diplomado ACVS, ECVS, ACVSMR



1

Hernias umbilicales



- **Gestación:**
 - Hernia umbilical fisiológica y temporal
 - Se retrae y el anillo peritoneal se cierra
 - Quedan venas y arterias umbilicales
- Hernia umbilical ocurre cuando el defecto de la pared abdominal superficial al anillo peritoneal persiste

2

Hernias umbilicales

- Hereditarias
- Hembras > machos
- PSI y Cuartos de Milla
- Estudio:
 - 44 WB - 5 a 11 meses
 - 19 hernias al nacimiento
 - Día 4: 18 palpación normal
 - 12: normal al nacimiento >> hernias en semana 5-8
 - Hernias adquiridas desaparecen espontaneamente menos



Equine Record (2008)
147, 27-29

E. Enzerink, DVM,
P. R. van Weeren, DVM,
PhD,
M. A. van der Velden,
DVM, PhD, Department of
Equine Sciences, Faculty
of Veterinary Medicine,
Utrecht University,
Vakgroep 12, NL-3584 CM
Utrecht, The Netherlands

Closure of the abdominal wall at the umbilicus and the development of umbilical hernias in a group of foals from birth to 11 months of age

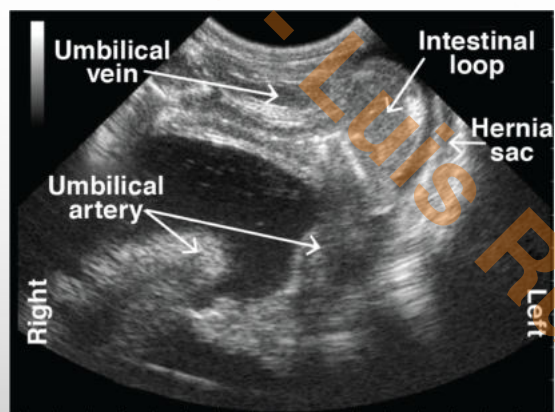
E. ENZERINK, P. R. VAN WEEREN, M. A. VAN DER VELDEN

The closure of the body wall defect at the umbilicus was studied in relation to the development of umbilical hernias in a group of 44 normal foals, 25 of which were followed from birth until five months of age, and 19 from birth until 11 months of age. At birth, 19 of the foals had a defect in the body wall at the umbilicus that was termed a 'palpable umbilical ring'. In 18 of them this defect disappeared within four days, but in the other the ring did not close and a hernial sac with abdominal contents was palpable. This foal was considered to be the only foal to have a truly congenital umbilical hernia. Twelve foals developed an umbilical hernia between five and eight weeks of age. The prevalence of umbilical hernias was much higher than in other studies, possibly owing to the prospective nature of the study.

3

Hernias umbilicales – Diagnóstico

- Fácil diagnóstico
- Ultrasonido
 - Examen de vena, arterias y uraco
 - Absceso?
 - Definitivamente en situaciones de cólico o signos clínicos de empeoramiento de la hernia



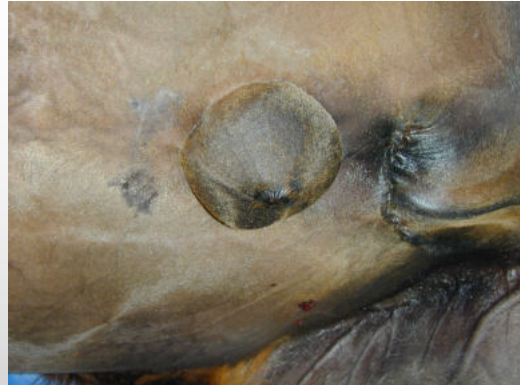(Magri M . In Practice 2018;40:301)

4

Hernias umbilicales - Tratamiento



- Pequeñas (<3cm):
 - Resolución espontánea 6-12 meses
 - Reducción manual repetida
- > 3 cm: tratamiento
 - Presente a 1 año de edad
 - Signos de encarceración (no se puede reducir), hernia dura, caliente, cólico




5

Hernias umbilicales - Tratamiento



- Bandas de goma
- Clamp
- Cirugía



(www.horsetalk.co.nz)

6

Hernias umbilicales - Tratamiento



Banda elástica o clamp

- Reducir contenido de hernia
- Torsionar saco herniario
- Banda pegada a pared abdominal
- Si desarrolla signos de colico:
 - Atrapamiento intestinal?
 - Retirar y aplicar más tarde
- Complicaciones pocas: 2/41
 - 1 cólico
 - 1 absceso
 - En 4: se cayó
 - 3 hernia se cerró
 - 1 cirugía



(www.horsetalk.co.nz)

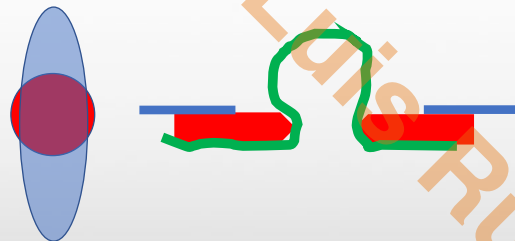
7

Hernia umbilical – Cirugía



Herniorrafia

- Se invade la cavidad peritoneal?
 - Técnica cerrada - No
 - Técnica abierta – Sí
 - En hernia encarcerada
 - Hernia no reducible
 - Dudas




8

Hernia umilical cirugia

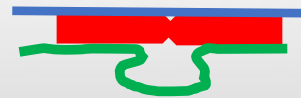


- Sutura
- Anillo herniario (pared abdominal)
 - Puntos sueltos
 - Absorbible
 - No. 0-1-2
- Subcutaneo
 - Continua/puntos sueltos
 - Absorbible
- Piel
 - Continua/puntos sueltos
 - Polipropileno

Abierta

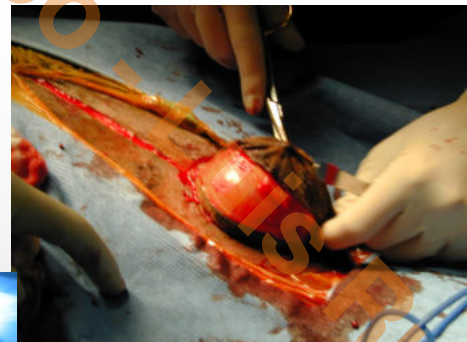
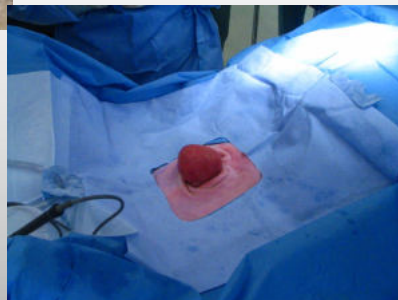
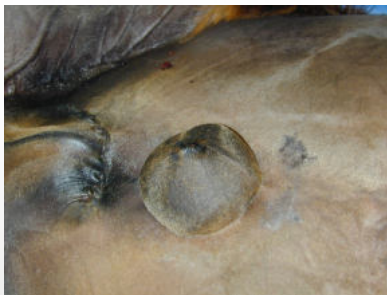

Cerrada



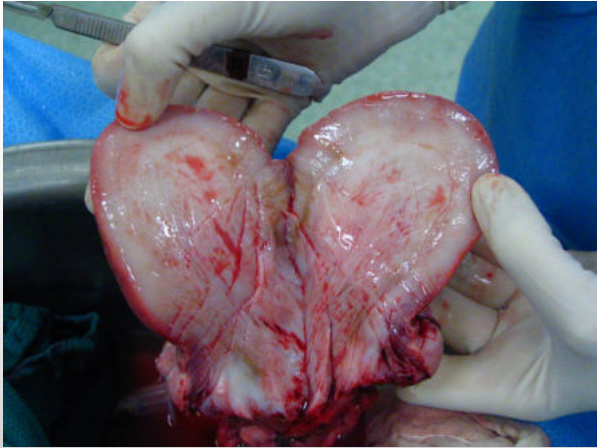
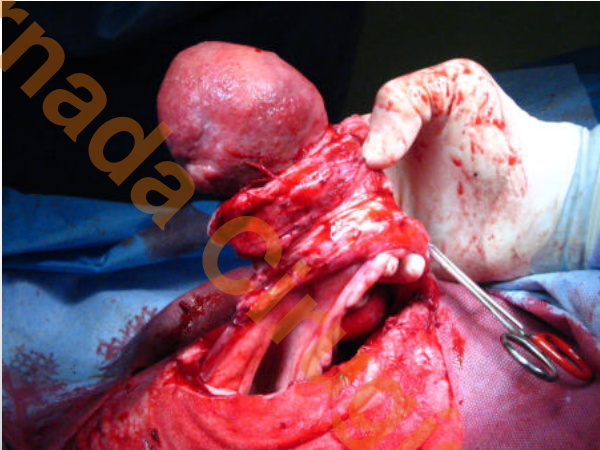
9

Hernia umbilicales – Cirugia herniorrafia



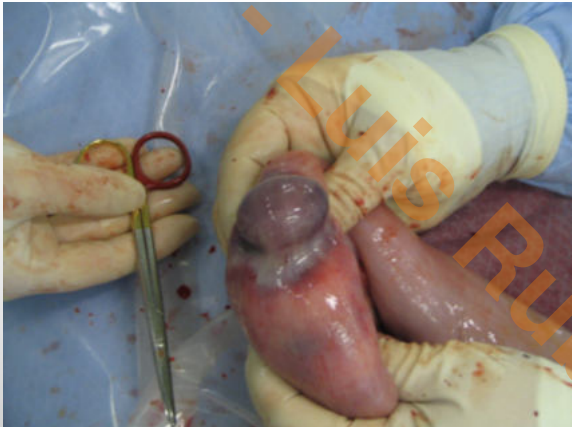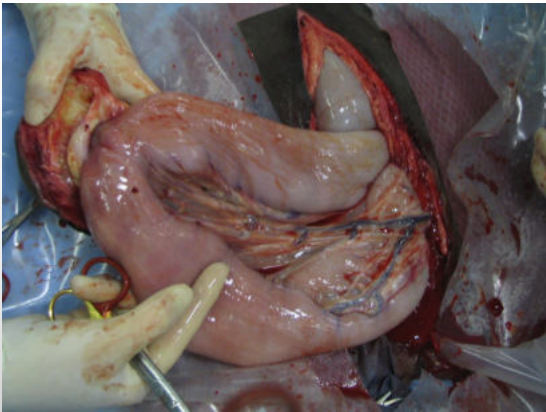
10

Hernia/masa umbilical



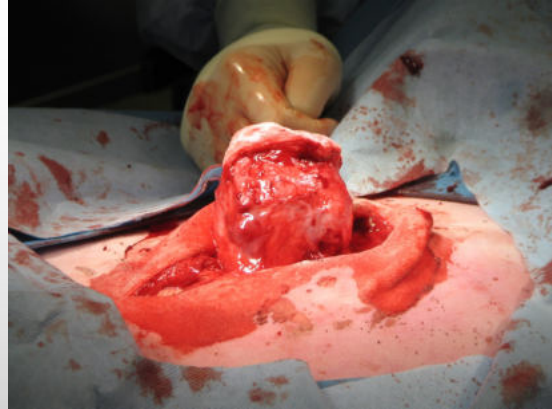
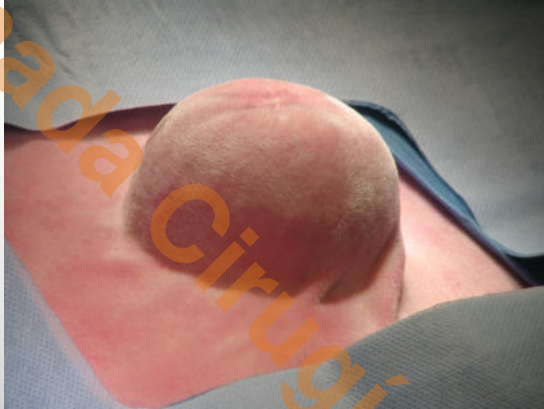11

Hernia umbilical



12

Hernia umbilical



13

Jornada Cirugía en Campo - Luis Rubio